



Full Length Research Article

Advancements in Life Sciences – International Quarterly Journal of Biological Sciences

ARTICLE INFO

Date Received: 26/12/2019;
Date Revised: 14/10/2020;
Date Published Online: 25/11/2020;

Authors' Affiliation:

1. ORIC, Lahore Garrison University - Pakistan
2. Department of Zoology, Government College University - Pakistan
3. Department of Urology, Mayo Hospital Lahore - Pakistan
4. Department of Orthopedics, National Defense Hospital - Pakistan

Corresponding Author:

Saira Khan
Email: sairakhan965@hotmail.com

How to Cite:

Khan S, Noor F, Sohail I, Imtiaz S, Anum F, Sarmad S, Kabir S, Raza S (2020). Hepatoprotective role of fruit extract of *Terminalia arjuna* in acetaminophen intoxicated mice. Adv. Life Sci. 8(1): 63-67.

Keywords:

Acetaminophen; Hepatocurative; Hepatoprotective; Serum Enzymes; *Terminalia arjuna*

Open Access



Hepatoprotective role of fruit extract of *Terminalia arjuna* in acetaminophen intoxicated mice

Saira Khan^{1*}, Faiza Noor², Imran Sohail², Sarmad Imtiaz³, Faiza Anum¹, Sana Sarmad⁴, Shoaib Kabeer¹, Shahid Raza¹

Abstract

Background: Liver injury and dysfunction is one of the major health concerns throughout the world. Several herbal formulations are reported to exert beneficial effects on the biochemistry of the liver.

Methods: Therefore, the current project is conducted to evaluate the hepatocurative and hepatoprotective potential of *Terminalia arjuna* by using albino mice.

Results: The fruit extract (400 mg/Kg) of the plant showed hepatoprotective effects upon pre-treatment for 5, 10 and 15 days and later challenged with acetaminophen (400 mg/Kg) for 3 days. The results showed substantial protective properties as there was comparatively less damage to the liver. Furthermore, the fruit extract of *T. arjuna* also exhibited hepatocurative effects when animals were given acetaminophen (400 mg/Kg) for 3 days to damage the liver followed by the treatment with the plant extract (400 mg/Kg) for 5, 10 and 15 days. The results also indicated hepatocurative activities, as the elevated serum levels of hepatic enzymes were inclining to normal ranges in a time-dependent manner.

Conclusion: In conclusion, the fruit extract of *T. arjuna* possesses hepatoprotective plus hepatocurative activities.



Introduction

In modern medicinal practices, plants have occupied the central stage for preparation of some important drugs to treat different ailments. World Health Organization (WHO) estimated that 65-80% population living in developing countries uses herbs for the treatment of their ailments. Therefore, the progress as well as estimation of new therapeutic agents from phytonutrients is encouraged. Furthermore, only 15% of existing plant species has been evaluated for their pharmacological activities. Therefore, it's important for evaluating herbal plants for their medicinal potential [1-12].

Liver is concerned with metabolism and detoxification of these compounds; therefore, this vital organ is more vulnerable to toxicity. Hence, it is required to find out the cheapest and safest ways to combat the hazardous effects of the toxins on the liver. Recent research on herbal plants has opened the window to search for therapeutically active agents from medicinal plants that possess antioxidative potential and provides protection to these organs/tissues from unwanted damage and oxidative stress [14-22].

Terminalia arjuna, is commonly found in Pakistan, is a well-known medicinal plant and has been reported for its antitussive, diuretic, cardiogenic, homeostatic, laxative, antidiabetic and anti-cancerous activities. Although, unlike parts of *T. arjuna* like bark, leaves, as well as roots have been extensively explored for protection against different diseases, the fruit extract of this plant is little investigated [26-32]. The bark extract of *T. arjuna* contains arjunolic acid, polyphenols, flavonoids, triterpenoid, alkaloids, glycosides, saponin and tannins, utilized for the treatment of liver disorders, hyperlipidaemia, coronary artery disease, heart failure and hypercholesterolemia. The fruit extract of this plant possesses flavonoids, gallic acid, glycosides, saponins, tannin, terpenoid, phenolic compounds and showed antimicrobial, antioxidant and cytoprotective activities. The present study was accomplished to explore the hepatoprotective as well as hepatocurative potential of *T. arjuna* fruit on paracetamol induced hepatotoxicity in animal models [33-37,39,40].

Methods

Plant collection and preparation of extract

The fruit of *T. arjuna* was collected from botanical garden of Government college university (GCU) Lahore, washed and shade dried for three days. These were then grounded and 500g of the powder was soaked in absolute ethanol for 14 days. Subsequently, the mixture was filtered. The filtrate was subjected to rotary evaporator (42-45°C) to obtain the plant extract which was stored at 4°C until further use.

Experimental animals

The male albino mice weighing 25-30g were kept in the animal house of GCU, Lahore at 21±1°C with 12 hours dark-light cycle and fed with standard diet and water. The study was performed according to the rules of departmental ethics committee. The study was

conducted according to the guidelines of animal ethics to minimize the pain to the animals.

Chemicals

Paracetamol (Acetaminophen) was used for liver intoxication. Test Kits for measuring Alanine transaminase (ALT), Alkaline phosphatase (ALP), Aspartate transaminase (AST) and Lactate dehydrogenase (LDH) were supplied by synchron® systems (Ireland).

Blood sampling

The animals were anesthetized and 1 ml blood was collected directly from heart in Eppendorf. Subsequently, the serum from blood sample was isolated by centrifuging at 4000 rpm (rotation per minute) for 10 minutes 4°C. After centrifugation straw colored serum was obtained and subjected for analysis of enzymes.

Histopathological studies

Following collection of blood, the mice were subjected for sacrifice and the livers were carefully removed for histopathological studies. The liver tissues were rinsed with normal saline solution, fixed in 10% formalin and stained with hematoxylin-eosin.

Experimental Plan

Hepatoprotective studies

The animals were divided into the five groups of five animals each. In negative control group the mice were fed on standard diet and water. For positive control, paracetamol (400mg/Kg) administered to mice for 3 days [26,28] to damage the liver and blood was collected for LFTs (liver function tests) and liver for histological studies. For hepatoprotective (HP) studies, the animal of group HP₅, HP₁₀ and HP₁₅ were given the fruit extract (400 mg/Kg body weight/day [10,12] for five, ten and fifteen days, respectively. Subsequently, the animals were challenged with paracetamol (400 mg/Kg body weight/ day). Blood samples were taken as of each group for analysis of liver enzymes. Furthermore, the liver sections of negative, positive and HP₁₅ groups were collected for histological studies.

Hepatocurative studies

In order to study the hepatocurative effect of the plant extract, the mice were divided into the five groups of five animals each. In the negative group animals were fed on standard diet and water. For positive control paracetamol was given to the mice for three days to damage the liver. For hepatocurative (HC) studies, the animals were first challenged with paracetamol (400 mg/Kg body weight/day) for three days to damage the liver. Then the fruit extract (400 mg/Kg body weight/day) was given orally for five, ten and fifteen days to HC₅, HC₁₀ and HC₁₅ groups, respectively. Subsequently, the blood samples were collected from each group for analysis of liver enzymes. Furthermore, the liver sections of negative, positive and HC₁₅ groups were collected for histological studies.

Statistical analysis

The data were analyzed by using ANOVA (One-way Analysis of Variance). The probability not as much of 0.05 ($P < 0.05$) was considerable.

Results

Hepatoprotective treatment

For hepatoprotective studies, the serum levels of ALT, AST, ALP and LDH are shown in table I. In paracetamol treated group (+ve control), the serum level of these enzymes were significantly elevated as compared to the normal group (-ve control), whereas the level of ALT, AST, ALP and LDH decreased significantly with pre-treatment with fruit extract of *T. arjuna* for 5 days (HP₅), 10 days (HP₁₀) and 15 days (HP₁₅) followed by the administration of acetaminophen for 3 days in each group. Furthermore, the results showed that effect was time-dependent as maximum protection was observed in HP₁₅ group. The hepatoprotective effect of the *T. arjuna* extract is further confirmed by the histological studies. However, for qualitative analysis only the liver section of fifteen-day treatment (HP₁₅) was compared with the liver sections of positive and negative control groups (Figure 1). The livers of acetaminophen-intoxicated mice (positive control) showed the distortion of hepatocytes, spillage of lymphocytes and loss of cellular integrity. The histological observations of the livers of the mice pre-treated with fruit extract of *T. arjuna* preserved the architecture of liver indicating the plant extract possesses the hepatoprotective effects (Figure 1).

Treatment	Parameters studied			
	ALT (U/L)	AST (U/L)	ALP (U/L)	LDH (U/L)
Negative Control (Normal diet)	26.0 ± 0.8	32.4 ± 0.8	20.2 ± 0.2	6.5 ± 1.2
Positive Control (Normal diet + 3 days Acetaminophen)	42.4 ± 0.8	55.4 ± 0.6	40.3 ± 0.7	37.0 ± 1.4
HP5 (<i>T. arjuna</i> 5 days + Acetaminophen 3 days)	33.4 ± 0.9*	45.7 ± 0.7*	37.0 ± 0.3*	20.7 ± 0.6*
HP10 (<i>T. arjuna</i> 10 days + Acetaminophen 3 days)	29.7 ± 0.4*	40.0 ± 0.6*	30.0 ± 0.4*	16.6 ± 0.4*
HP15 (<i>T. arjuna</i> 15 days + Acetaminophen 3 days)	24.8 ± 0.3*	35.4 ± 0.5*	26.1 ± 0.5*	14.1 ± 0.3*

Table I: Effect of pre-treatment with *T. arjuna* fruit extract on serum concentrations of liver enzymes of mice in paracetamol induced hepatotoxicity (Mean ± SD).

Treatments	Parameters studies			
	ALT (U/L)	AST (U/L)	ALP (U/L)	LDH (U/L)
-ve Control (Normal diet)	26.0 ± 0.8	32.4 ± 0.8	20.2 ± 0.2	6.5 ± 1.2
+ve Control (Normal diet + 3 days Acetaminophen)	42.4 ± 0.8	55.4 ± 0.6	40.3 ± 0.7	37.0 ± 1.4
HC5 (Acetaminophen 3 days + <i>T. arjuna</i> 5 days)	37.1 ± 0.5*	46.4 ± 0.4*	34.2 ± 0.3*	21.1 ± 0.4*
HC10 (Acetaminophen 3 days + <i>T. arjuna</i> 10 days)	32.8 ± 0.4*	31.8 ± 0.6*	27.9 ± 0.5*	9.6 ± 0.2*
HC15 (Acetaminophen 3 days + <i>T. arjuna</i> 15 days)	27.3 ± 0.6*	24.9 ± 0.7*	24.5 ± 0.4*	8.7 ± 0.3*

Table II: Effect of post-treatment with *T. arjuna* fruit extract on serum concentrations of liver enzymes of mice in paracetamol induced hepatotoxicity (Mean ± SD).

Hepatocurative treatment

For hepatocurative studies, the serum concentrations of ALT, AST, ALP and LDH is shown in table II. In paracetamol treated group (+ve control), the serum level of these enzymes was significantly elevated as

compared to the normal group (-ve control). However, the concentration of ALT, AST, ALP and LDH were significantly lowered with the administration of paracetamol for three days followed by treatment with fruit extract of *T. arjuna* for 5 (HC₅), days (HC₁₀) and 15 days (HC₁₅). The liver histology also confirmed the hepatocurative effect of the plant extract. The livers of acetaminophen-intoxicated mice showed destruction of the cellular architecture indicating the extent of live damage. However, the cellular integrity is restored by treatment with the plant extract (Figure 1).

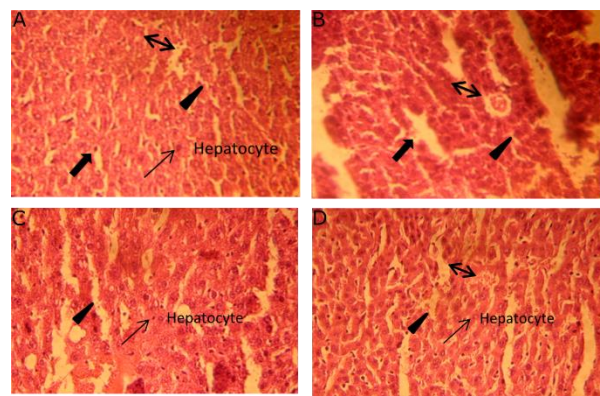


Figure 1: Fruit extract of *T. arjuna* showed hepatoprotective as well as hepatocurative activities against acetaminophen induced hepatotoxicity. (A) Architecture of normal liver (negative control group). (B) Upon treatment with acetaminophen (positive control) for three days, the liver is damaged which is evident by distortion of hepatocytes integrity, spillage of lymphocytes and loss of cellular boundaries. (C) Pre-treatment of mice with the plant extract for 15 days followed by exposure to acetaminophen for three days. The plants showed hepatoprotective effect as the hepatocyte architecture is comparable to that of negative control. (D) The liver of the mice were first challenged with acetaminophen for three days which were then treated with the plant extract for 15 days. The extract exhibited hepatocurative activity as the liver architecture reverted to the normal. H & E (40x magnification). Symbol representation: (↔) Central vein; (▶) sinusoid; (▶) lymphocyte infiltration; (→) nucleus of hepatocyte.

Discussion

Increasing sophisticated information highlights various breakthroughs in pharmacogenomics. Emerging evidence suggests that there are escalating drug induced toxicological responses that result in serious health hazards [26, 27]. Our data demonstrates that phytonutrients have broader implications in terms of recapitulation of normal liver biomarker values after administration.

Paracetamol is a well-recognized antipyretic and analgesic agent. In therapeutic doses, it is safe and is eliminated as glucuronide and sulfate. However, at toxic doses the sulfation and glucuronidation pathways are saturated. In this condition, paracetamol is oxidized by cytochrome P-450 to N-acetyl-p-benzoquinone imine (NAPQI), which is a highly reactive agent. The NAPQI covalently binds to the glutathione and other cellular proteins and subsequently results in disturbance of

calcium homeostasis, mitochondrial injury, oxidative stress and ultimately cellular damage [15,25].

In present study paracetamol was used as toxic agent and the therapeutic effects of *T. arjuna* fruit extract were investigated by comparing liver biomarker values. The serum levels of ALT, AST, ALP and LDH were evaluated in the control and test groups. The serum concentrations of these enzymes were elevated after the liver damage with paracetamol that underwent considerable decline upon administration of the fruit extract. Furthermore, the plant extract showed the protection to the liver architecture indicating the hepatoprotective potential of this plant. The effect was time-dependent because the maximum protection was found after 15 days of administration of fruit extract. Our results are in concordance with Subasini et al. [38] who found that the bark extract of *T. arjuna* possesses hepatoprotective activities. Similarly, the leaf extract of this plant is also reported to exhibit hepatoprotective activity [5]. Our results are also in line with the studies of [24] with reference to reversal of toxicological responses of various drugs by administration of aqueous extract of *T. arjuna*.

The protective effect of the plant extracts might be because of protection of hepatocyte membrane integrity or regeneration of the damaged liver cells. It has been reported that the extract of *T. paniculata* significantly improved the blood and liver thiols levels of the rats challenged with acetaminophen [13]. In a similar mechanism the fruit extract of *T. arjuna* might also elevate the glutathione level of the hepatocytes that binds with NAPQI and ultimately lessens the toxic effects of this metabolite of paracetamol. It has also been documented that the extract of the *T. arjuna* possesses flavonoids and tannins [23]. These compounds can facilitate the regeneration of hepatic cells and stabilization of the plasma membrane. However, further study will provide details of the phytochemicals which are responsible for the protective effect and the mechanism of action.

It is concluded that hepatocurative activities, as the elevated serum levels of hepatic enzymes were inclining to normal ranges in a time-dependent manner. The fruit extract of *T. arjuna* may potentially be used as a therapeutic agent to cure paracetamol induced liver damage in humans.

Acknowledgment

We are thankful to Professor Dr. Zaheer-Un-Din Khan, Ex-Chairperson Botany Department, Government College University Lahore, Pakistan for his assistance in identification of plants.

Author Contributions

Mohammad Imran Sohail planned the study. Mohammad Imran Sohail, Saira Khan and Faiza Noor performed experiments. Saira Khan, Faiza Anum and Mohammad Imran Sohail contributed to write the manuscript.

Statement of Conflict of Interest

The authors declare that no conflict of interest exists.

References

1. Abbas Z, Khan SM, Alam J, Khan SW, Abbasi AM. Medicinal plants used by inhabitants of the Shigar Valley, Baltistan region of Karakorum range-Pakistan. *Journal of Ethnobiology and Ethnomedicine*, (2017); 13: 53.
2. Ali BH, Bashir AK, Rasheed RA. Effect of traditional medicinal plants *Rhazya stricta*, *Balanitis aegyptiaca* and *Haplophyllum tuberculatum* on paracetamol induced hepatotoxicity in mice. *Phytotherapy Research*, (2001); 15: 598-603.
3. Amal raj A, Gopi S. Medicinal properties of *Terminalia arjuna* (Roxb.) Wight & Arn.: a review. *Journal of Traditional and Complementary Medicine*, (2017); 7(1): 65-78.
4. Bishop S, Liu SJ. Cardioprotective action of the aqueous extract of *Terminalia arjuna* bark against toxicity induced by doxorubicin. *Phytomedicine*, (2017); 36: 210-216.
5. Biswas M, Karan TK, Kar B, Bhattacharya S, Ghosh AK, Kumar RBS, Haldar PK. Hepatoprotective activity of *Terminalia arjuna* leaf against paracetamol induced liver damage in rats. *Asian Journal of Chemistry*, (2011); 23:1739-1742.
6. Chaudhari GM, Mahajan RT. *In vitro* hepatoprotective activity of *Terminalia arjuna* stem bark and its flavonoids against CCl₄ induced hepatotoxicity in goat liver slice culture. *Asian Journal of Plant Science Research*, (2016); 6(6): 10-17
7. De Luca V, Salim V, Atsumi SM, Yu F. Mining the biodiversity of plants: a revolution in the making. *Science*, (2012); 336(6089): 1658-1661.
8. Gohar UF, Mukhtar H, Mushtaq A, Farooq A, Saleem F, et al. Fungi: A potential source of biopharmaceuticals. *Agrobiological records*, (2020); 2: 49-62.
9. Imran M, Cao S, Wan SF, Chen Z, Saleemi MK, et al. Mycotoxins – a global one health concern: A review. *Agrobiological records*, (2020); 2: 1-16.
10. Dhanabal SP, Syamala G, and Suresh B. Hepatoprotective activity of the Indian medicinal plant polygala arvensis on D- galactosamine induced hepatic injury in rats. *Fitoterapia*, (2006); 77(6): 472-474.
11. Dwivedi S, Jauhari R, 1997. Beneficial effects of *Terminalia arjuna* in coronary artery disease. *Indian Heart Journal*, (1997); 49: 507–510.
12. Dwivedi S. *Terminalia arjuna*, Wight and Arn- A useful drug for cardiovascular disorders. *Journal of Ethnopharmacology*, (2007); 114:114-129.
13. Eesha BR, Amberkar VM, Kumari KM, Sarath B, Vijay M, Lalit M, Rajput R. Hepatoprotective activity of *Terminalia paniculata* against paracetamol induced hepatocellular damage in Wistar albino rats. *Asian Pacific Journal of Tropical Medicine*, (2011); 4(6): 466-469.
14. Fahmy NM, Al-Sayed E, Singab AN. Genus terminalia: A phytochemical and Biological Review. *Medicinal & Aromatic Plants*, (2015); 4: 218.
15. Foufelle F, Formenty B. 2016. Role of endoplasmic reticulum stress in drug-induced toxicity. *Pharmaceutical Research*, (2016); 4(1): 211.
16. Ghosh J, Das J, Manna P, Sil PC. Cytoprotective effect of arjunolic acid in response to sodium fluoride mediated oxidative stress and cell death via necrotic pathway. *Toxicology in Vitro*, (2008); 22: 1918–1926
17. Ghosh J, Das J, Manna P, Sil PC. Protective effect of the fruits of *Terminalia arjuna* against cadmium-induced oxidative stress and hepatic cell injury via MAPK activation and mitochondria dependent pathway. *Journal of Food Biochemistry*, (2010); 123: 1062–1075.
18. Goswami HK, Ram HK. Ancient food habits dictate that food can be medicine but medicine cannot be “food”. *Medicines*, (2017); 4: 82.
19. Ilyas U, Katare DP, Aeri V, Naseef PP. A review on hepatoprotective and immunomodulatory herbal plants. *Pharmacogenomics*, (2016); 10(19): 66-70.
20. Jaeschke H, McGill MR, Ramachandran A. Oxidant stress, mitochondria, and cell death mechanisms in drug induced liver injury: lessons learned from acetaminophen hepatotoxicity. *Drug Metabolism Reviews*, (2012); 44: 88–106.
21. Ji S, Fattahi A, Raffel N, Hoffmann I, Beckmann MW, Dittrich R, Schrauder M. Antioxidant effect of aqueous extract of four plants with therapeutic potential on gynecological diseases; *Semen persicae*, *Leonurus cardiaca*, *Hedyotis diffusa*, and *Curcuma zedoaria*. *European Journal of Medical Research*, (2017); 22(1): 50.

22. Karunakaran G. Cardioprotective role of methanolic extract of bark of *Terminalia arjuna* against in-vitro model of myocardial ischemic-reperfusion injury. *Ancient Science of Life*, (2015); 35(2): 79-84.
23. Mandal S, Patra A, Samanta A, Roy S, Mandal A, Mahapatra TD, Pradhan S, Das K, Nandi DK. Analysis of phytochemical profile of *Terminalia arjuna* bark extract with antioxidative and antimicrobial properties. *Asian Pacific Journal of Tropical Biomedicine*, (2013); 3(12): 960-966.
24. Manna P, Sinha M, Sil CP. Aqueous extract of bark of *Terminalia arjuna* plays a protective role against sodium fluoride induced hepatic and renal oxidative stress. *Journal of Natural Medicines*, (2007); 61:251-260.
25. Michaut A, Moreau C, Robin MA, Fromenty B. Acetaminophen-induced liver injury in obesity and nonalcoholic fatty liver disease. *Liver International*, (2014); 34: 171–179.
26. Montanari F, Pinto M, Khunweeraphong N, Wlcek K, Sohail MI, Noeske T, Boyer S, Chiba P, Stieger B, Kuchler K, Ecker GF. Flaggging drugs that inhibit the bile salt export pump. *Molecular Pharmacology*, (2014); 13(1): 163-171.
27. Morgan RE, van Staden CJ, Chen Y, Kalyanaraman N, Kalanzi J, Dunn RT, Afshari CA, Hamadeh HK. A multifactorial approach to hepatobiliary transporter assessment enables improved therapeutic compound development. *Toxicology Science*, (2013); 136(1): 216-241.
28. Mustafa ZHA, Ali AKA, Qaw FS, Cader ZA. Cimetidine enhances the hepatoprotective action of N- acetylcysteine in mice treated with toxic doses of Paracetamol. *Toxicology*, (1997); 121: 223-228.
29. Owk AK, Lagudu MN. *In vitro* antimicrobial activity of mature fruits of *Terminalia arjuna* Wight & Arn. *World Journal of Pharmacy and Pharmaceutical Sciences*, (2016); 5(5): 766-774.
30. Raghvan B, Kumari SK. Effect of *Terminalia arjuna* stem bark on antioxidant status in liver and kidney of alloxan diabetic rats. *Indian Journal of Physiological Pharmacology*, (2006); 50: 133–142.
31. Rahmat ullah M, Noman A, Shahadat MD, Hossan MD, Rashid HO, Rahman T, Choudhury MH, Jahan R. A survey of medicinal plants in two areas of Dinajpur district, Bangladesh including plants which can be used as functional foods. *American-Eurasian Journal of Agricultural & Environmental Sciences*, (2009); 3: 862-876.
32. Rao BK, Sudarshan RP, Rajasekhar MD, Nagaraju N, Rao AC. Antidiabetic activity of *Terminalia pallida* fruit in alloxan induced diabetic rats. *Journal of Ethnopharmacology*, (2003); 85:169-172.
33. Roy A, Bhoumik D, Sahu RK, Dwivedi J. Medicinal plants used in liver protection: A review. *UK Journal of Pharmaceutical and Biosciences*, (2014); 2: 23-33.
34. Saleem A, Husheem M, Harkonen P, Pihlaja K. Inhibition of cancer cell growth by crude extract and the phenolics of *Terminalia chebularetz* Fruit. *Journal of Ethnopharmacology*, (2002); 117: 123-129.
35. Singh G, Singh AT, Abraham A, Bhat B, Mukherjee A, Verma R, Agarwal SK, Jha S, Mukherjee R, Burman AC. Protective effect of *Terminalia arjuna* against Doxorubicin- induced cardiotoxicity. *Journal of Ethnopharmacology*, (2008); 117: 123-129.
36. Sivalokanathan S, Ilayaraja M, Balasubramanian MP. Efficacy of *Terminalia arjuna* (Roxb.) on N-nitrosodiethyl amine induced hepatocellular carcinoma in rats. *Indian Journal of Experimental Biology*, (2005); 43(3): 264-7.
37. Sohail M I, Mughal MS, Arshad N, Arshad M. Incidence of hepatitis B and C in industrial areas of Sheikhpura and Kasur. *Pakistan Journal of Zoology*, (2010); 42(6): 673-677.
38. Subasini, V., Raja manileam, G.V., Dubey, G.P., Prabu, P.C., Sahayam, C.S., Shabi, M.M., Gayathri, K. and Agrawal, A. Hydroalcoholic extract of TA. A potential hepatoprotective herb. *Journal of Biological Sciences*, (2007); 7: 255-262.
39. World Health Organization. The World traditional medicines situation in traditional medicines: Global Situation, Issues and Challenges. Geneva, (2011); 3:1–14.
40. Zahra K, Sohail MI, Malik MA. Effect of *Momordica charantia* (bitter melon) on serum glucose level and various protein parameters in acetaminophen intoxicated rabbits. *Journal of Intercultural Ethnopharmacology*, (2012); 1(1): 7-12.



This work is licensed under a Creative Commons Attribution-Non Commercial 4.0 International License. To read the copy of this license please visit: <https://creativecommons.org/licenses/by-nc/4.0/>