



Full Length Research Article

Advancements in Life Sciences – International Quarterly Journal of Biological Sciences

ARTICLE INFO

Open Access



Date Received:
24/07/2024;
Date Revised:
15/11/2024;
Available Online:
31/12/2024;

Author's Affiliation:

1. Department of Surgery and
Obstetrics, College of Veterinary
Medicine, University of Basrah,
Basrah – Iraq
2. Department of Microbiology,
College of Veterinary Medicine,
University of Basrah, Basrah – Iraq

*Corresponding Author:

Mohammed R. Abduljaleel
Email:
mohammed.resen@uobasrah.edu.iq

How to Cite:

Jasim MM, Naeem RM,
Abduljaleel MR, Sanad NH,
Ibrahim AA (2025).
Efficacy of autogenic,
allogenic and heterogenic
platelet rich plasma (PRP) on
Avulsion skin wounds in
rabbit model. Adv. Life Sci.
12(1): 91-97.

Keywords:

Platelet rich plasma; Rabbit;
Skin; Wound

Editorial Note:

You are viewing the latest
version of this article having
minor corrections related to
the use of English language.

Efficacy of autogenic, allogenic and heterogenic platelet rich plasma (PRP) on Avulsion skin wounds in rabbit model

Mohammed M. Jasim¹, Rafid Majeed Naeem¹, Mohammed R. Abduljaleel^{1*}, Noor Hassan Sanad¹, Alaa Ahmed Ibrahim¹, Haider Rasheed Alrafas²

Abstract

Background: Wound healing through second intention was prone to issues. As a result, there is a strong need in veterinary medicine for therapies that hasten the healing of secondary wounds. These studies demonstrate the effect of autogenic, allogenic, and heterogenic PRP on healing of wounds.

Methods: Six rabbits weighing (1.8-2.5 kg), blood samples were collected from the rabbits and goats. Skin markings of 1cm in diameter were made on dorsal midlines. These wounds were allocated into four groups, control, autogenic, allogenic, and heterogenic PRP treated groups. Planimetric monitoring to determine the diameter (mm) and histologically were performed at 3,7,15, and 21 days after injury.

Results: Clinically, on day fifteen there were improvements in wound contraction in the Auto and Allo PRP groups, better than control. There was slight improvement in the Hetero PRP group. After 21 days of wounding, the Auto and AlloPRP group's wounds were fully healed. Histologically, after 1 week, the AutoPRP and AlloPRP groups revealed scab formation. However, in the XenoPRP and control groups the a thick scab covered the incision line. After 2nd week of post wounding, the two treated groups were nearly similar compared with the XenoPRP and control group including scab detachment. At the end of the 3rd week, The NS group revealed partially detached scab formation. While all treated showed a complete regeneration of the epidermis layer, new hair follicles beneath the regenerated epidermis.

Conclusion: For the promotion of wound repair processes, Autogenic and Allogenic PRP therapy may represent a straightforward, affordable, and successful option.



Introduction

By surface area, the skin represents the body's biggest organ. It is the vital component that protects interior tissues against abrasion, microbial infection, UV light, and high temperatures. Due to its high risk of harm, it has a considerable effect on both individual animals patients and the health industry [1]. Animals' quality of life suffers as a result of wounds, which can result from a variety of causes and frequently result in both physical and psychological pain [2]. Wound healing is still a difficult clinical issue, thus proper, effective wound treatment is crucial. Integrated cellular and metabolic cascades that restore the structural and functional health of the injured tissue make [3]. The injured tissues repair occurs as a sequence of events, which consists of inflammation, proliferation, and remodeling (migration of different cell types). The inflammatory stage begins after an injury, initially with vasoconstriction that causes homeostasis and releases various mediators of inflammation. Hemostasis may be designated as the initial phase, preceding inflammation. A series of processes, including inflammation, cell growth, and remodeling (cell type movement), lead to the healing of wounded tissues. After an injury, the inflammatory stage starts, first with vasoconstriction that leads to homeostasis and releases a variety of inflammatory mediators. It is possible to refer to hemostasis as the earliest stage before inflammation [4,5].

Vasoconstriction, platelet release response, clot formation, and the release of growth factors and proinflammatory cytokines are the dominant processes during the hemostasis phase. Following this comes the inflammatory phase, which is characterized by the proliferation of leukocytes, macrophages, and neutrophils, and the macrophages are responsible for phagocytosis of microorganisms and wound debridement [6]. The proliferative phase, which overlaps the preceding phase, is mostly made up of granulation tissue formation by fibroblasts, angiogenesis, and contraction of wounds by myofibroblasts [7]. In 1956, Billingham and Russell came to the conclusion that contracture, or the forced inward migration of the wound borders in response to tensile stresses created within the wound, is what causes the full-thickness coetaneous wounds in rabbits to heal definitively. Due to contracture, the skin's histological and functional continuity have nearly fully recovered [8].

The remodeling stage is characterized by reformulations and improvements in the collagen fiber's constituent parts that boost tensile strength. During the remodeling phase, the wound's vascularization recovers to normal and collagen remodeling takes place [1]. Insufficient oxygenation or

perfusion, repeated trauma, and severe inflammation are the causes that make a wound chronic. Several growth factors, including platelet-derived growth factors (PDGF), epidermal growth factor (EGF), transforming growth factor beta (TGF- β), platelet activation factor (PAF), and others, appear to be required for the beginning and enhancement of wound healing [7,9].

Animal models have been created for the study of the intricate cellular and biochemical procedures involved in wound healing as well as for testing the efficacy and security of possible therapeutic medicines. Reproducibility, quantitative interpretation, therapeutic relevance, and effective clinical translation are all goals that should be pursued with animal models. The choice of a species of animal for wound research should take into account a number of parameters. They consist of price, accessibility, handling convenience, familiarity with investigators, and human likeness [10]. One important screening approach for evaluating potential novel treatments is the rabbit model. Despite being somewhat bigger than the mice and rats that are more frequently utilized as research animals, these creatures are nevertheless manageable and reasonably priced. The skin of the rabbit is thick, and elastic has a significant surface area of skin tissue in comparison to its size. Before cell migration and matrix remodeling, the rabbit's wounds constrict to their greatest extent during the healing process. Therefore, research aimed to examine innovative medicines including cell therapy, platelet concentrates, and laser therapy can benefit from using rabbits as helpful models [11].

To hasten healing and encourage high-quality tissue repair, a platelet concentrates with a high concentration of growth factors (GF), which has been employed in numerous medical sectors, may be used. A number of growth factors, including transforming growth factor beta (TGF- β), growth factor derived from platelets (PDGF), the growth factor for vascular endothelial cells (VEGF), and epidermal development factor (EGF), have been discovered in PRP [12]. The elevated levels of these growth factors during the healing phase of injury enables an increase in angiogenesis, which stimulates proliferation, migration, and differentiated cells, as well as an increase in collagen formation. Autogenic PRP which means prepared after collecting blood from the same animals, in allogenic PRP the blood collected from same species, but xenogeneic blood taken from other species. Allogenic or heterologous PRP can be used if a patient's own blood cannot be obtained, and platelet-rich plasma, also known as PRP, has been widely explored as a biomaterial for wound therapy [2]. Surgical treatment or traumatic tissue loss can result in

acute wounds. a surgical procedure that removes a soft tissue tumor from the skin layer and underlying parenchyma, for instance, might occasionally leave a sizable, albeit uncontaminated, wound that cannot heal by primary intention because of the sizable defect in the tissue. Traumatic injuries also occur regularly [5]. Wound treatment strategies are widely discussed in the literatures and these strategies are involving a large number of studies based on various types of substances, especially biomaterials ex. PRP, MSCs [2,3]. The proper method of wound care can significantly affect the clinical result [5]. The best topical wound treatment solution should be biocompatible and nontoxic, and capable of accelerating healing without impeding the progress of the body's natural healing mechanisms. There is currently no one best therapy that speeds up the healing of problematic wounds [3].

The purpose of this investigation was to assess and contrast (Histologically and clinically) the impact of autogenic, allogenic, and heterogenic PRP on rabbit model cutaneous wound healing.

Methods

Animal ethics

In accordance with the BCVM regulations of the college of Veterinary Medicine University of Basrah, the study received ethical committee approval.

Animals of the study

Six rabbits weighing around 1.8-2.5 kg were utilized for the research. All the animals are adequately caged and maintained with meal and water, housed in a well-ventilated room.

PRP Preparation

5–6 ml of blood was collected from animals (rabbits to autogenic and allogenic, and from the goat to xenogeneic) (Figure 1-a) and immediately transported to 15ml sterile centrifuge tube. Then transported to a veterinary internal medicine laboratory. The initial centrifugation was performed at a relatively low speed (1,050 r/min, 8 cm centrifugation radius, 100 ×g). Following the removal of the erythrocyte layer, two centrifugations at comparatively high speeds (400 × g, 2,100 r/min, and 8 cm centrifugal radius) were carried out twice for duration of 10 minutes each. The tube's bottom was where the platelet-rich plasma layer was deposited, then by sterile syringe directly applied on the site of wound (Figure 1-f) [13].

Surgical procedure

The animals were anesthetized by combination of ketamine (13mg/kg B.W) and xylazine (5mg/kg B.W) [14]. The skin is shaved, cleaned, and then disinfected. Skin markings of 1 cm in diameter were made in the rabbits' dorsal midline on each side of the body when

they were completely aseptic (see Figures 1, b, and c). After that, four complete thicknesses of the designated skin were carefully sliced (Figures 1, d, and e). These wounds were divided into four groups: the control group, which received standard saline treatment; the autogenic, allogenic, and xenogenic PRP treatment groups. Each rabbit has members from all the groups (Figure 1, f).

Clinical Parameters

Measurement of the wound diameter (mm) was monitored planimetrically at 3rd, 7th, 15th, and 21 days after injury. The study of skin wound healing is shown by wound contraction data analyses.

Histopathological study

The skin samples were harvested for histopathological examination in 7-, 15-, and 21-days post- wounding.

Statistical analysis

data were analyzed statistically by One-Way ANOVA with numerous comparisons testing utilizing a statistical soft- ware program (SPSS for Microsoft Windows version 20, USA). The clinical data were reported as mean values with standard errors. Differences were judged significant at (P < 0.05).

Results

Clinical results

All of the treated groups and control (normal saline group) showed no significant difference in wound diameter on the third and seventh-day post-wounding. But on day fifteen there was a significant improvement in wound contraction in the Auto and Allo PRP groups 2.32±0.23, 2.38±0.27 better than control (Normal saline group) 4.16±0.36. However, there was a slight improvement in Xeno PRP group 2.9±0.27 but it was not significant. After 21 days of wounding, the Auto and Allo PRP group's wounds were fully healed. The wound diameter in the Xeno PRP group 1.2±0.12 was slightly better than the control group 1.98±0.08 but the improvement had no significant difference statistically. The differences in the diameter according to the time post wounding in the same group were significant in the Auto and Allo PRP groups, but in the Xeno PRP group, there were no significant differences between the 3rd and 7th day and between the 15th and 21st day. In the control group, there was no significant difference in wound contraction between 15th and 21st days (Figure 5, table one). Wound contraction study, the diameter of the wounds for Auto PRP, Allo PRP, Xeno PRP, and Normal Saline groups.

Histopathological results

First week

In the 1st week post-surgery, the histopathological changes of the NS group showed the formation of a thick scab covering the incision line and the appearance of the epithelial tongue, collagen fibers, fibroblasts, and newly formed blood vessels (Figures 2, a). While the AlloPRP group revealed partially detached scab formation from the beneath dermis layer, the presence of regenerated stratum basale epi- dermis layer and construction of epithelial tongue and newly formed blood and edema were present (Figures 2, b). The Auto PRP group almost showed histological changes similar to the Allo PRP group including; a scab partially covering the wound area, and regenerated stratum basale layer prominently, an accumulation of collagen fibers and new blood vessels in the dermal layer, and edema also present (Figures 2, c). The Xeno PRP group also showed similar changes in the composition scab covering the wound area, and the regenerated stratum basale layer was prominent. Edema between the epidermis and dermis layer was evident, formation of the epithelial tongue (EP) and new blood vessels were distinguished (Figure 2, d).

Second week

In the 2nd week post-surgery, The NS group showed thick scab formation and a massive accumulation of granulation tissue beneath the thick scab. There was severe infiltration of polymorph and monomorphic inflammatory cells in the wound area and enormous granulation tissue accumulation was prominent (Figure 3, a). The expansion of collagen fibers, and congestion of blood vessels in the dermis layer. While the AlloPRP group showed thick partially detached scab formation from the beneath the layer, hemorrhage between scab and dermis was evident, and a thin regenerated stratum basale cells were initiated.

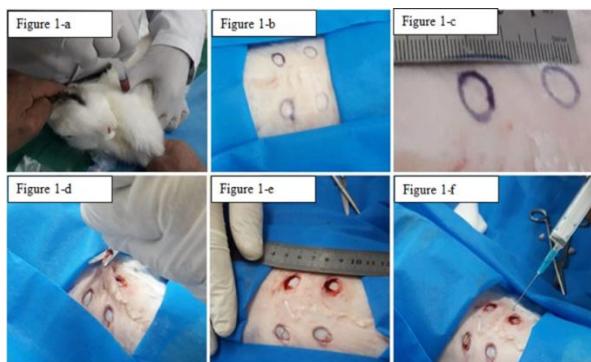


Figure 1: a: blood samples were collected from the heart of rabbits; b, and c: the dorsal skin of the rabbit was prepared surgically, and four (1 cm) circular shapes were marked on both sides of the dorsal midline; d and e: the full thickness of marked skin areas were cut carefully; f: application of PRP on the skin wound.

Types of groups	Auto PRP group	Allo PRP group	Xeno PRP group	Normal Saline Group
Wound-diameter according The times post wounding / Day				
Wound diameter at 3 rd day	6.3±0.61 ^{aA}	6.76±0.28 ^{aA}	6.03±0.61 ^{aA}	7.28±0.26 ^{aA}
Wound diameter at 7 th day	5.72±0.17 ^{aB}	5.98±0.19 ^{aB}	6.02±0.27 ^{aA}	6.66±0.39 ^{aB}
Wound diameter on 15 th day	2.32±0.23 ^{aC}	2.38±0.27 ^{aC}	2.9±0.27 ^{abB}	4.16±0.36 ^{bC}
Wound diameter on 21 st day	0.00±0.00 ^{aD}	0.00±0.00 ^{aD}	1.2±0.12 ^{abB}	1.98±0.08 ^{bC}

Table 1: Wound contraction study, the diameter of the wounds for Auto PRP, Allo PRP, Xeno PRP, and Normal Saline groups post wounding, in different times post wounding (means and standard errors). ab Different letters within each row indicate significant differences (P<0.05). ABCD Different letters within each column indicate significant differences (P<0.05).

The epithelial tongue and newly formed blood vessels were prominent and the infiltration of inflammatory cells (Figure 3, b) a hemorrhage between the scab and dermis was evident. The histopathological changes of the AutoPRP group include the presence of a thick scab covering the affected area, and regenerated stratum basale. Incompletely regenerated stratum granulosum, stratum spinosum, and stratum basale layers of the epidermis were evident (Figures 3, c). In addition, severe hemorrhage and infiltration of a few inflammatory cells in the dermis were prominent. Almost the histological features in the XenoPRP group were similar to the AutoPRP group, with the formation of a thick scab covering the affected wound area and a thin regenerated stratum basale layer of the epidermis. Moreover, the presence of hemorrhage in the dermis layer was evident (Figure 3, d).

Third week

In the 3rd week post-surgery, The NS group revealed partially detached scab formation from the beneath dermis layer. Also, the presence of regenerated stratum basale epidermis layer spinosum and construction of epithelial tongue and construction of epithelial tongue stratum, newly formed blood vessels, congestion and/or hemorrhage was evident in the dermis layer (Figures 4, a). The histopathological features recorded in the Allo- PRP group include complete regeneration of the epidermis layer and dermis layer. Infiltration of few inflammatory cells and several congested and newly formed blood vessels was prominent (Figure 4, b). The AutoPRP group showed complete regeneration of the epidermis layer, and massive fibroblasts in the dermis layer and newly formed blood vessels were evident (Figures 4, c). The XenoPRP group showed normal epidermis and dermis layers. There are newly formed hair follicles and congested blood vessels. The angiogenesis process was observed, and it characterized by congested blood vessels; infiltration of

few lymphocytes, and dendritic cells was evident (Figures 4, d). In addition, the proliferation of fibroblasts and regenerated hair follicle were apparent.

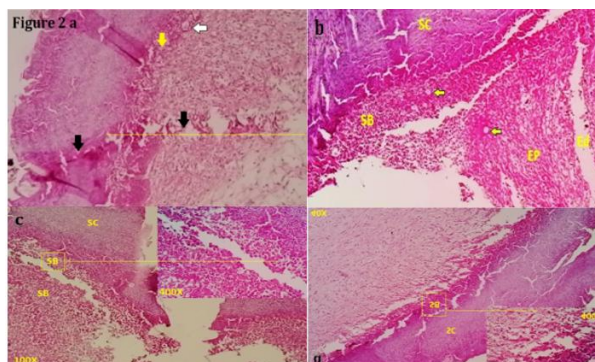


Figure 2: Histopathological section of skin at 1st week post wounding. a) NS group showed the presence of a thick scab covering the incision line (black arrow and yellow line), regenerated eosinophilic basal epidermal layer (yellow arrow), and newly formed blood vessels (white arrow). H&E, 100X. b) AlloPRP group section of skin revealed scab (Sc) formation partially detached from the beneath dermis layer, the presence of regenerated stratum basale epidermis layer (SB), and newly formed blood vessels (yellow arrows) construction of epithelial tongue (EP) and edema also present. H&E, 100X. c) AutoPRP group showed scab (SC) partially covers the wound area, and the regenerated stratum basal layer was prominent (SB). H&E 100X, Focused area (400X). d) XenoPRP group showed scab (SC) cover the wound area, regenerated stratum basale layer (SB) was prominent (SB), and oedema between the epidermis and dermis layer was evident. H&E 40X, Focused area (400X).

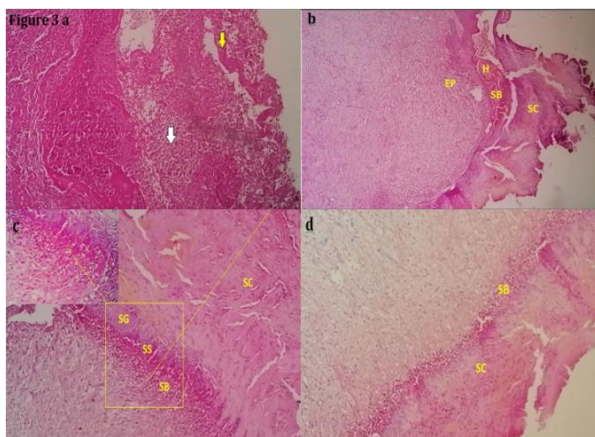


Figure 3: Histopathological section of skin at the 2nd week post wounding. a) NS group showed massive accumulation of granulation tissue (yellow arrow) beneath the thick scab and severe infiltration of inflammatory cells (white arrow) in the wound area. H&E, 100X. b) AlloPRP group showed thick scab (SC) formation partially detached from the beneath layer, haemorrhage (H) between scab and dermis was evident, a thin regenerated stratum basale cells (SB) were initiated, and epithelial tongue in the dermis layer was prominent. H&E, 40X. c) AutoPRP group showed a thick stratum corneum layer (SC) and the presence of incompletely regenerated stratum granulosum (SG), stratum spinosum (SS), and stratum basale (SB) layers of the epidermis. H&E, 100X. d) XenoPRP group showed the formation of a thick scab (SC) covering the affected wound area and a thin regenerated stratum basale layer (white arrow) of the epidermis. H&E, 100X.

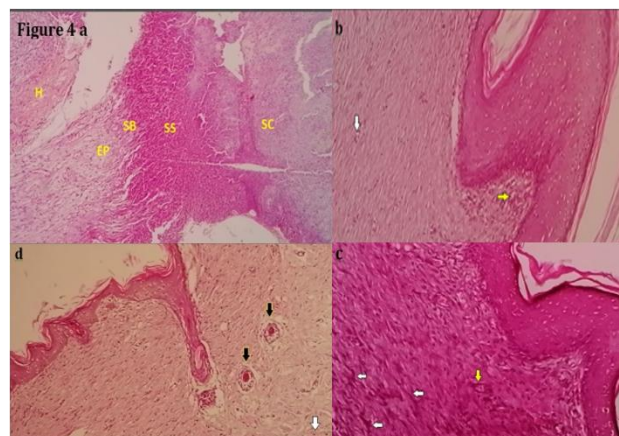


Figure 4: Histopathological section of skin at the 3rd week post wounding. a) NS group revealed scab (Sc) formation partially detached from the beneath dermis layer, presence of regenerated stratum basale epidermis layer (SB), stratum spinosum (SS) and construction of epithelial tongue (EP); also haemorrhage (H) was evident in the dermis layer. H&E, 100X. b) AlloPRP group showed complete regeneration of epidermis layer and dermis layer. There are newly formed blood vessels (yellow arrow) and infiltration of few inflammatory cells (white arrow). H&E, 100X. c) AutoPRP group showed complete regeneration of epidermis layer, and massive accumulation of fibroblasts (white arrows) in the dermis layer and newly formed blood vessels (yellow arrows) were evident (white arrows). H&E, 100X. d) XenoPRP showed normal epidermis and dermis layers. There are newly formed hair follicles (black arrows) and congested blood vessels (white arrows). H&E, 100X.

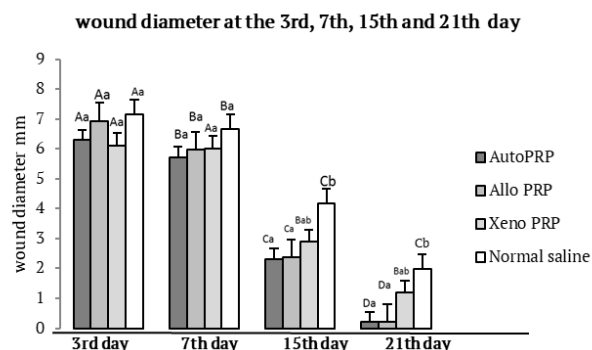


Figure 5: Wound contraction study, the diameter of the wounds for Auto PRP, Allo PRP, Xeno PRP, and Normal Saline groups post wounding (3rd, 7th, 15th, 21st days). ABCD Different letters within the group indicate significant differences (P< 0.05). ab Different letters among groups indicate significant differences (P< 0.05).

Discussion

Second-intention healing depends on wound contraction, which is the centripetal or concentric shrinkage in the size of an open wound. Granulation tissue myofibroblasts pulling pressures on the borders of the skin and fibroblast activity in collagen in the granulation tissue are what induce wound contraction. Contraction may result in a full and normal healing of the wound [15]. All of the treated groups and control (normal saline group) showed no significant difference in wound diameter on the third and seventh day because the contraction of the wound depends on the

myofibroblast cells. These cells are differentiated from the fibroblasts formed in the granulation tissue (the proliferation stage), which is initiated approximately seven days after full-thickness avulsion incision [16].

In days fifteen and twenty-one, there was a significant improvement in wound contraction in the Auto and Allo PRP groups better than the control (Normal saline group). Growth factors included in PRPs encourage the movement of cells, their proliferation, and differentiation, all of which are necessary for accelerated wound healing [17].

In 2024, [18] stated that the underlying scientific theory behind PRP therapy is that an injection of concentrated platelets at sites of injury may start tissue repair via the release of numerous biologically active factors (cytokines, growth factor, lysosomes), adhesion proteins, and revascularization. The platelet-poor plasma fraction (PPP) also contains plasma proteins such as fibrinogen, prothrombin, and fibronectin. PRP concentrates can induce the supraphysiological release of growth factors to quicken recovery from acute injuries and chronic wounds.

In 15th and 21th day after wounding, There were slight improve in Xeno PRP group but it was not significant, Predictably, the biological efficacy and results of clinical trials are affected by the absolute PRP concentration, purity, and biological characteristics of PRP and related products, which vary greatly [18]. According to the time post wounding, Auto PRP and Allo PRP groups showed regular definitive differences in wound contraction better than Xeno PRP group and Control group (Normal saline), The elevated growth factor content and minimal immunogenicity of auto and allo PRP promoted cutaneous wound healing by reducing inflammation, boosting angiogenesis, and enhancing wound contraction. 15 rabbits' backs with full-thick skin wounds were treated with PRP. The outcomes of the study disagreed with our findings since the PRP groups had considerably lower contraction rates after two weeks than the controls [19].

After 1 week, the AutoPRP and AlloPRP groups revealed partially detached scab formation from the beneath dermis layer, the presence of regenerated stratum basal epidermis layer, and the construction of epithelial tongue and oedema present. However, in the XenoPRP and control groups, the thick scabs cover the incision line. These results showed that auto and allo PRP improve granulation tissue accelerate proliferate stage including epithelial cells. The results came in agree with [20,21]. They claimed that PRP is a plentiful supply of growth factors and that it significantly altered the production of proinflammatory cytokines and chemokines by monocytes, which in turn stimulated tissue regeneration. It also agreed with [2] who studied surgically induced rabbits skin injury

treated with heterogonous PRP gel, they found the crust was present in both groups (the control and treated group) with no further clinical symptoms present at any of the investigated periods. Collagen production and wound contraction rates did not vary across groups. They concluded that the heterogonous PRP gel was unable to boost collagen production and hasten wound healing. There were no local adverse effects, although both groups' wound-healing processes were effective and comparable.

After 2nd week post wounding, the histopathological changes in treated groups were nearly similar to alloPRP group comparing with the XenoPRP group (The formation of a thick scab covering the affected wound area) and control group. There was thick partially detached scab formation from the beneath the layer, haemorrhage between scab and dermis was evident, a thin regenerated stratum basale cells were initiated. The epithelial tongue and newly formed blood vessels were prominent and infiltration of inflammatory cells. Nevertheless, in the control group, there was thick scab formation and massive accumulation of granulation tissue beneath the thick scab. Furthermore, there was severe infiltration of polymorph and monomorphic inflammatory cells in the wound and expansion of collagen fibers, congestion of blood vessels in the dermis layer. The improvement in these two treated wounds showed the action of myofibroblast which collaborate in contraction of the wound and detachment of the scab and hemorrhage.

The results in accordance with [22]. He created test wounds on the skin of pigs, and he discovered that when there is a superficial wound in the skin, new epidermis replaces the denuded region via migration from the sweat gland ducts and hair follicles inside the wound, as well as from the surface epidermis at the wound borders. The dry scab that typically covers a superficial wound delays epithelialization; if the scab forms prematurely, the pace of epithelialization is noticeably accelerated.

At the end of the 3rd week, The NS group revealed partially detached scab formation from the beneath dermis layer. Also, the presence of regenerated stratum basale epidermis layer spinosum and construction of epithelial tongue and construction of epithelial tongue stratum, newly formed blood vessels, and congestion was evident in the dermis layer. While all treated groups showed the nearly the same histopathological changes, there was complete regeneration of the epidermis layer, oedema, and new hair follicles beneath the regenerated epidermis. Furthermore, oedema and infiltration of a few polymorphs inflammatory cells and fibroblasts were evident. In addition, newly formed hair follicles were apparent. These findings demonstrated that PPR regulates a wide range of cells involved in

tissue healing [23]. A straightforward, affordable, and successful option to encourage full-thickness wound healing procedures in rabbits might be autogenic and allogenic PRP therapy. While xenogenic PRP treatment has no significant effect (wound contraction) on these wounds, however, it has no adverse effect on wound healing, and it might be better to be used when there are no other sources of auto and allo PRP.

Author Contributions

Mohammed Majid Jasim, Rafid Majeed Naeem, and Mohammed Resen Abduljaleel, contributed to the overall research design and manuscript preparation, Original Manuscript Draft, Writing – Editing, and Revisions. Mohammed Majid Jasim contributed to the animal's preparation and surgery operation. Rafid Majeed Naeem performed the majority of experiments, and the analysis of some data presented in the manuscript. Mohammed Resen Abduljaleel contributed to the surgery operation, Analysis and interpretation of data of all experimental groups. Noor Hassan Sanad, Alaa Ahmed Ibrahim and Haider Rasheed Alrafas assisted with collecting data for animal experiments including performing and measuring the clinical signs and assisted in the statistical analysis and interpretation of some data. All authors read and approved of the final manuscript.

Conflict of Interest

The authors declare no conflict of interest.

References

- Rodrigues M, Kosaric N, Bonham CA, Gurtner GC. Wound healing: a cellular perspective. *Physiological reviews*, (2019); 99(1): 665-706.
- Nogueira RMB, Marques MEM, Laposy CB, dos Santos Silva ML, Breda MR, et al. Collagen quantification in rabbit dermal wounds treated with heterologous platelet-rich plasma gel. *Semina: Ciências Agrárias*, (2017); 38(1): 249-258.
- Abu-Seida AM. Effect of propolis on experimental cutaneous wound healing in dogs. *Veterinary medicine international*, (2015); 2015(1): 672643.
- Thiruvoth FM, Mohapatra DP, Kumar D, Chittoria SRK, Nandhagopal V. Current concepts in the physiology of adult wound healing. *Plastic and Aesthetic Research*, (2015); 2: 250-256.
- Velnar T, Bailey T, Smrkolj V. The wound healing process: an overview of the cellular and molecular mechanisms. *Journal of international medical research*, (2009); 37(5): 1528-1542.
- Ellis S, Lin E, Tartar D. Immunology of Wound Healing. *Current Dermatology Reports*, (2018); 7 (4): 350-358.
- George Broughton I, Janis JE, Attinger CE. Wound healing: an overview. *Plastic and reconstructive surgery*, (2006); 117(7S): 1e-S-32e-S.
- Abdi R. Paul Russell: the transcendentalist surgeon of America. *Frontiers in Transplantation*, (2023); 2: 1191149.
- Ravishankar K, Kiranmayi GVN, Prasad YR, Devi L. Wound healing activity in rabbits and antimicrobial activity of *Hibiscus hirtus* ethanolic extract. *Brazilian Journal of Pharmaceutical Sciences*, (2019); 54(04): e17075.
- Grada A, Mervis J, Falanga V. Research techniques made simple: animal models of wound healing. *Journal of Investigative Dermatology*, (2018); 138(10): 2095-2105. e2091.
- Lemo N, Marignac G, Reyes-Gomez E, Lilin T, Crosaz O, et al. Cutaneous reepithelialization and wound contraction after skin biopsies in rabbits: a mathematical model for healing and remodelling index, (2010); 80 (5): 637-652.
- Lacci KM, Dardik A. Platelet-rich plasma: support for its use in wound healing. *The Yale journal of biology and medicine*, (2010); 83(1): 1.
- Wang L, Zhao L, Shen L, Fang Q, Yang Z, et al. Comparison of the effects of autologous and allogeneic purified platelet-rich plasma on cartilage damage in a rabbit model of knee osteoarthritis. *Frontiers in Surgery*, (2022); 9: 911468.
- Jassim MM, Abduljaleel MR, Abdulkareem ZB, Sanad NH, Alrashid IM. Study the effect of the magnetic field on the healing of bone fracture after implant avian bone in femoral bone in rabbits. *Advances in Animal and Veterinary Sciences*, (2023); 11(11): 1779-1784.
- Ono I, Tateshita T, Inoue M. Effects of a collagen matrix containing basic fibroblast growth factor on wound contraction. *Journal of Biomedical Materials Research: An Official Journal of The Society for Biomaterials, The Japanese Society for Biomaterials, and The Australian Society for Biomaterials and the Korean Society for Biomaterials*, (1999); 48(5): 621-630.
- Bai J, Zeng X. Computational modeling and simulation of epithelial wound closure. *Scientific reports*, (2023); 13(1): 6265.
- Xia Y, Zhao J, Xie J, Lv Y, Cao DS. The efficacy of platelet-rich plasma dressing for chronic nonhealing ulcers: a meta-analysis of 15 randomized controlled trials. *Plastic and Reconstructive Surgery*, (2019); 144(6): 1463-1474.
- Fareez IM, Liew FF, Widera D, Mayeen NF, Mawya J, et al. Application of platelet-rich plasma as a stem cell treatment-an attempt to clarify a common public misconception. *Current Molecular Medicine*, (2024); 24(6): 689-701.
- Rajesh A, Harman RM, Van de Walle GR. Platelet Rich Plasma and Stem Cell Therapy. *Techniques in Small Animal Wound Management*, (2024); 233-251. John Wiley & Sons, Inc.
- El-Sharkawy H, Kantarci A, Deady J, Hasturk H, Liu H, et al. Platelet-rich plasma: growth factors and pro-and anti-inflammatory properties. *Journal of periodontology*, (2007); 78(4): 661-669.
- Xu P, Wu Y, Zhou L, Yang Z, Zhang X, et al. Platelet-rich plasma accelerates skin wound healing by promoting re-epithelialization. *Burns & trauma*, (2020); 8: tkaa028.
- Yampolsky M, Bachelet I, Fuchs Y. Reproducible strategy for excisional skin-wound-healing studies in mice. *Nature Protocols*, (2024); 19(1): 184-206.
- Li Y, Shao C, Zhou M, Shi L. Platelet-rich plasma improves lipopolysaccharide-induced inflammatory response by upgrading autophagy. *European Journal of Inflammation*, (2022); 1721727X221112271.



This work is licensed under a Creative Commons Attribution-NonCommercial 4.0 International License. To read the copy of this license please visit: <https://creativecommons.org/licenses/by-nc/4.0/>